

Improving Esthetics *with* Sequential Treatment Planning *and* **Implant-Retained Dentures**



by **Timothy F. Kosinski, DDS, MAGD**

While oral function is the primary concern for most patients, the importance of esthetics should not be underestimated. In addition to compromising oral health, conditions such as tooth decay, periodontal disease and edentulism can significantly affect a person's appearance. The deterioration or loss of teeth, bone and soft tissue decreases support for the lips and facial structures, with results ranging from wrinkling around the mouth to sag or collapse of the patient's facial features. These esthetic issues can negatively impact the self-confidence, social interactions and personal relationships of the patient. By restoring form as well as function, implant therapy can substantially improve the quality of life for patients. Thus, it is crucial that clinicians address esthetic needs with the same careful consideration applied to health and functional factors when planning and carrying out treatment.

For many patients, conventional dentures do not offer adequate prosthetic stability and retention, which can interfere with chewing, speech and other crucial oral functions. Additionally, an unstable denture may not provide sufficient support for the soft tissue surrounding the patient's mouth, negatively impacting facial esthetics. To address these problems, implant-supported dentures can be prescribed, dramatically improving prosthetic stability, comfort and functioning.¹ For these edentulous patients, implant-retained dentures also convey a sense of healthy and natural-

looking dentition by providing firm support for the patient's lips, smile and facial features. Additionally, dental implants minimize bone resorption, helping to mitigate deterioration of the patient's facial structures.² By preserving or improving oral esthetics, implant-retained dentures address one of the biggest challenges presented by edentulism.

Implant dentistry has advanced to the point where cases can be diagnosed and treatment planned with flexibility. Dental function can be restored predictably with a wide range of prosthetic options. Each patient has unique needs that should be thoroughly evaluated not just in terms of the ultimate restoration, but also throughout the healing phase as the implants integrate and the soft tissue heals. The short- and long-term desires of the patient must be understood prior to any surgical intervention. Any approach that does not fully consider these factors puts patient acceptance of the final restoration at risk.

The following case demonstrates a treatment plan uniquely tailored to both the functional and esthetic needs and concerns of the patient. A sequential treatment plan was developed that not only provided for the long-term health and dental functioning of the patient, but also addressed the considerable esthetic problems caused by severe tooth decay and bone loss.

Case Report

A 45-year-old patient presented with severe tooth decay and pronounced gingival recession around his maxillary arch. Radiography indicated significant bone loss. The patient was very aware of the compromised esthetics of his natural teeth. He had been unhappy with his teeth for a long period of time, but decided he needed to act when they lost much of their bone support and were becoming painful to utilize. Though the patient was concerned with the long-term prognosis of his dental health, his most pressing concerns were esthetic. As a teacher who spends significant time speaking in front of classrooms full of students, the deteriorating state of his dentition, gingiva and facial esthetics was causing a high degree of self-consciousness, insecurity and social difficulty.

While several options were explored and presented to the patient, implant therapy offered the best treatment option for maintaining long-term function and restoring natural-looking esthetics. Given the gingival recession along the patient's upper arch and atrophied state of the maxillary ridge and dentition, the teeth were determined to be non-restorable. The patient did not present any significant medical conditions or contraindications. Careful radiographic and intraoral examination determined that implants could be predictably placed.

Because the patient was an educator, it was important to provide him with as much function and stability as possible during the integration process, which was projected to last four to five months. Removing all of his maxillary non-restorable teeth and placing a conventional transitional denture would have presented obvious limitations for the patient. Speaking, as well as function, would be dramatically compromised with a full-palatal-coverage denture. Perhaps most importantly, his emotional state would have been affected. Self-conscious about his appearance while working with young college students, the patient was adamant about treatment planning implant therapy in two stages to maximize dental esthetics during the healing phase.

A sequential treatment plan was required to address these unique esthetic concerns of the patient. This meant atraumatically removing the most decayed teeth along with those that required extraction to facilitate placement of four Inclusive® Tapered Implants (Glidewell Direct; Irvine, Calif.). The cuspids and molars were retained to stabilize and serve as anchors for the maxillary palateless temporary appliance. Then, the implants and healing abutments were placed. Immediate function was established, and the remaining natural teeth stabilized the denture well. This novel approach

immediately resolved his issues with pain, allowed superior initial function of the transitional removable appliance, improved esthetics and offered the patient the opportunity to evaluate the form and function of the temporary denture prior to final prosthetic construction. The transition from his natural teeth to this appliance went smoothly, minimizing any negative psychological and emotional effects.

Ultimately, Locator® attachments (Zest Anchors; Escondido, Calif.) would be utilized to retain a maxillary overdenture, which was designed with a palateless shape to maximize oral function and comfort. In the long term, dental implants would minimize further bone loss while providing a foundation for this stable and functional implant-retained overdenture. Besides preserving dental function, this appliance would provide support for the patient's lips, tissue and facial structures, improving the patient's smile and physical appearance, which were the patient's biggest concerns.³

Following approximately four months of implant integration, a final impression was taken using impression copings and a custom tray. This allowed for fabrication of the master cast. The teeth used to anchor the temporary appliance were still in place. The proper Locator attachments were selected and placed into the soft tissue model. Denture teeth were set around the anchor teeth on the master cast and several wax try-ins were completed to ensure proper esthetics and lip support. The goal of this sequential treatment approach was to achieve the esthetics the patient needed in the short term, knowing that the remaining teeth would be extracted during the delivery appointment for the final maxillary implant-retained overdenture.

The day the final prosthesis was delivered, the remaining teeth were anesthetized and atraumatically removed using Physics Forceps (Golden Dental Solutions Inc.; Detroit, Mich.). The preselected Locator attachments were torqued into position, and the final implant-retained overdenture was immediately seated.

Sequential treatment planning met the short- and long-term needs of the patient, who did not go a single day without a highly functioning denture. Partnering with a lab adept with the surgical, healing and restorative considerations needed to achieve such a plan was integral to the success of the case. The patient was extremely pleased with the esthetics of the final appliance, which offered excellent chewing and speech capability, and greatly enhanced the appearance of the patient's teeth, smile and facial structures.

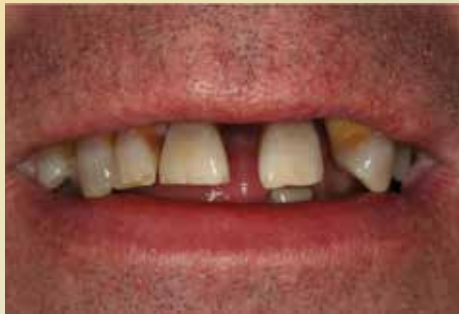

Figure 1: Preoperative smile exhibits poor oral esthetics about which the patient, a prominent educator that frequently engages in public speaking, was extremely self-conscious.

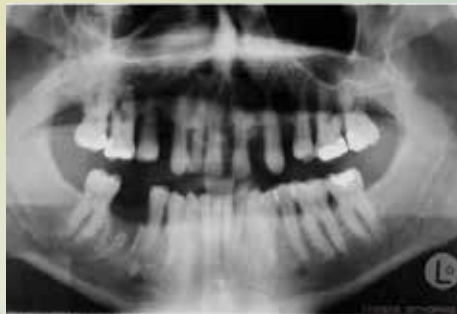

Figure 2: Panoramic radiograph indicates significant maxillary bone loss.

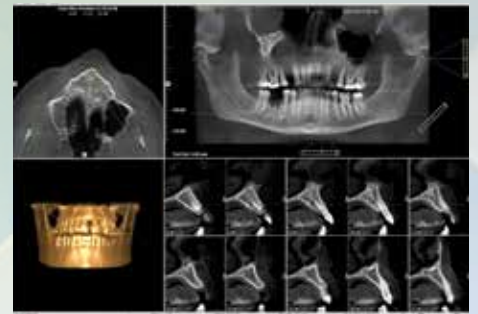


Figure 3: Preoperative cone-beam computed tomography (CBCT) scanning allowed visualization of the treatment plan prior to surgical intervention.

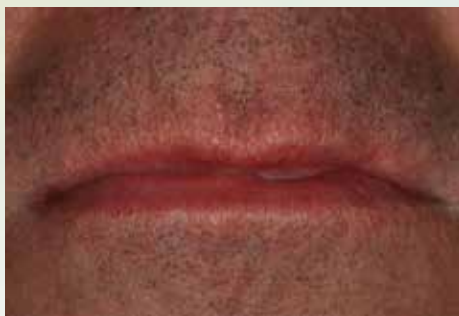

Figure 4: Closed-mouth esthetics demonstrate a thin upper lip that would make wearing a conventional denture difficult.

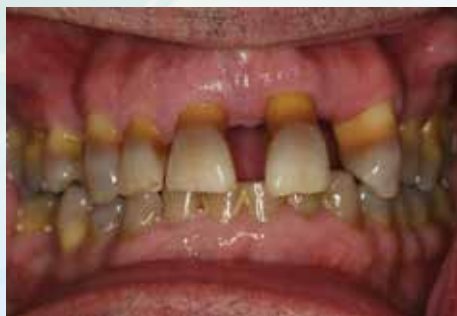

Figure 5: Retracted frontal view illustrates extremely poor esthetics resulting from severe dental decay and gingival recession.

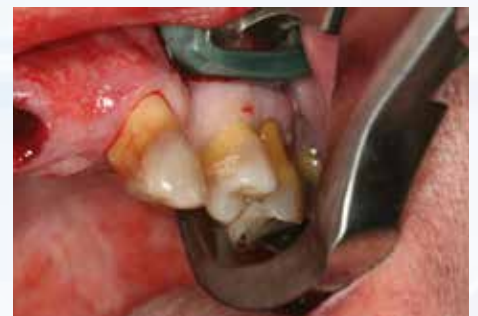

Figure 6: Several teeth along the maxilla were strategically extracted to facilitate ideal implant placement. Canines and molars were left in place to stabilize a horseshoe-shaped temporary prosthesis.

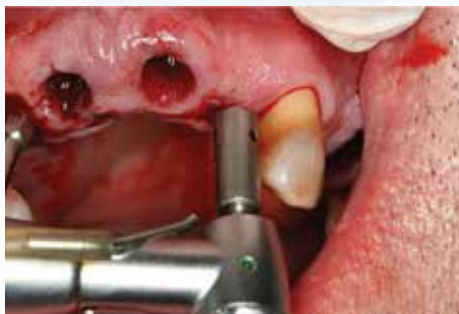

Figure 7: A tissue punch was used to provide a clean incision and access to the maxillary bone, facilitating a flapless procedure that minimized trauma to the soft tissue.

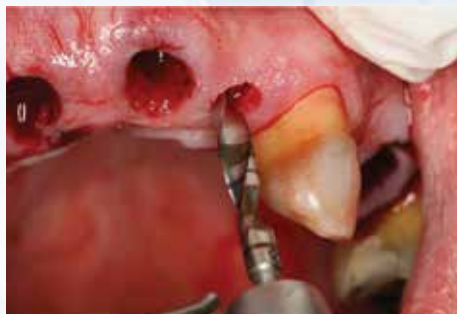

Figure 8: A series of progressively larger osteotomy burs was used to create the osteotomy site.

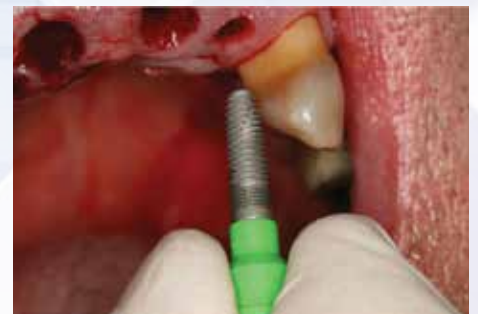

Figure 9: The first of four Inclusive Tapered Implants was initially hand threaded into place.

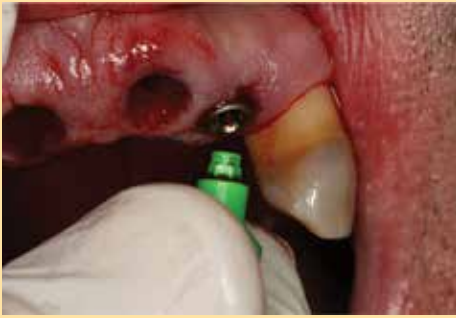

Figure 10: The implant disengaged with the plastic carrier upon reaching its torque threshold of approximately 15 Ncm.

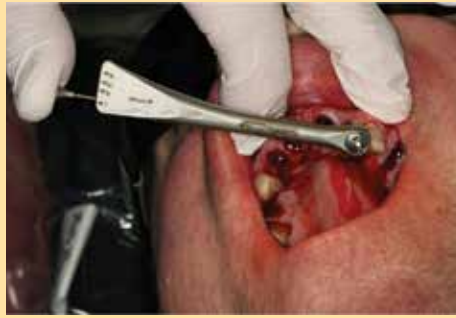

Figure 11: A torque wrench was used to torque the implant to 45 Ncm in proper position at the crest of the maxillary ridge.

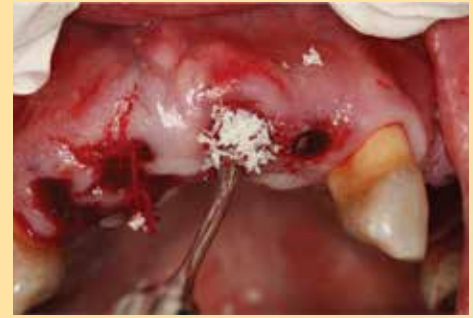

Figure 12: Cortico-cancellous bone grafting material was packed lightly into the central incisor socket site to prevent excessive bone loss.

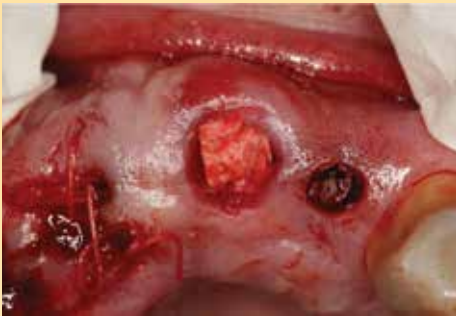

Figure 13: A non-resorbable barrier was engaged on the facial and palatal bone of the socket site prior to suturing the graft into position.

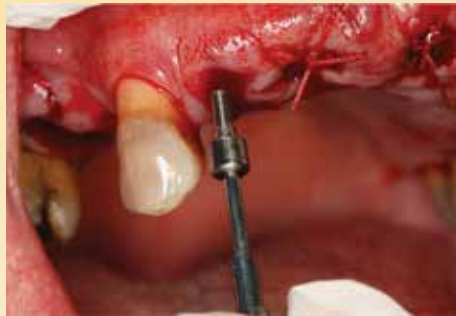

Figure 14: Healing abutments were threaded into place.

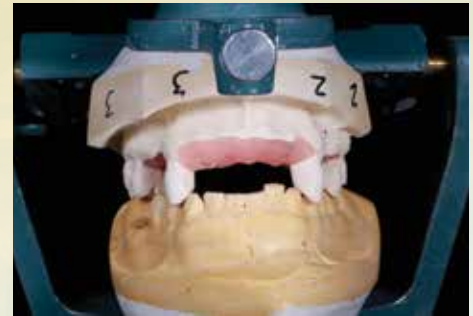

Figure 15: Prior to initial surgery, the lab fabricated and articulated casts of the maxillary and mandibular arches with only the anchor teeth in the upper arch.

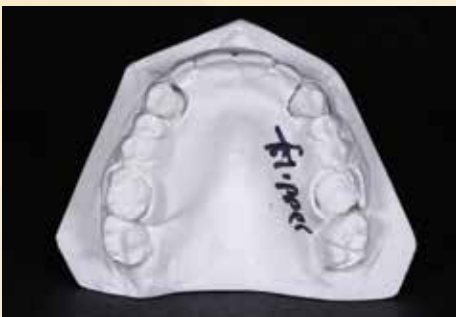

Figure 16: The lab produced a diagnostic wax-up of the maxillary arch including the anchor teeth and the partial denture, allowing for production of the temporary prosthesis prior to surgery.

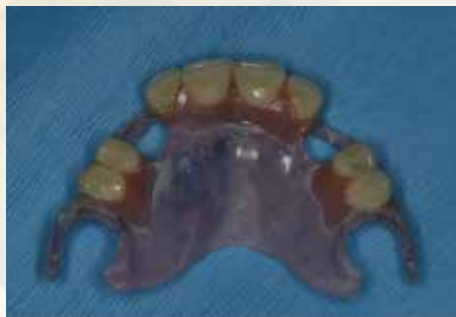

Figure 17: A transitional partial denture was fabricated, using the temporarily remaining maxillary teeth for retention.

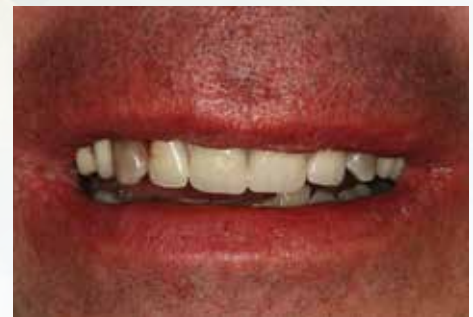
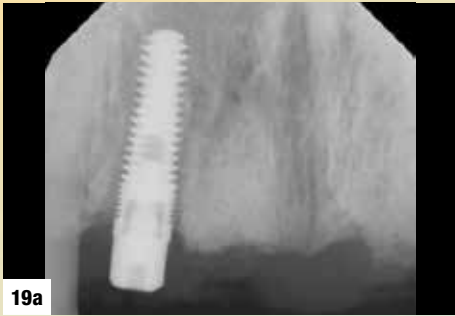
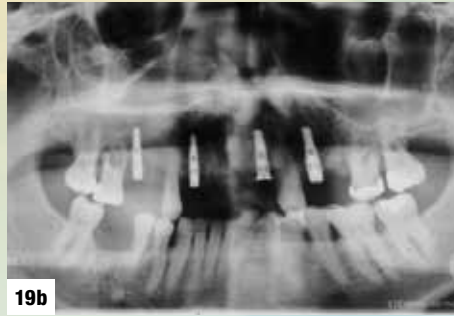Figure 18: The provisional appliance fit the patient well and maintained speech function effectively throughout the healing phase.



19a



19b

Figures 19a, 19b: Radiographs exhibit implants at proper depth, fully engaged with the maxillary bone.

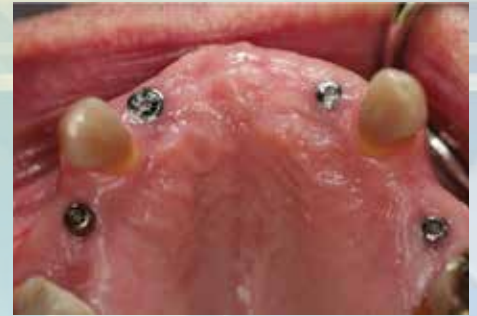

Figure 20: After approximately four months of integration, the soft tissue surrounding the implants was healthy and pink. The healing abutments, which allow for placement of impression copings without local anesthesia, were then removed.

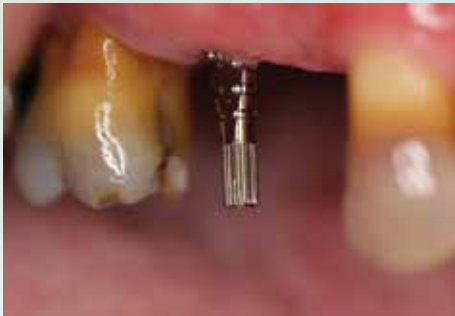

Figure 21: Impression copings were placed into the implants.

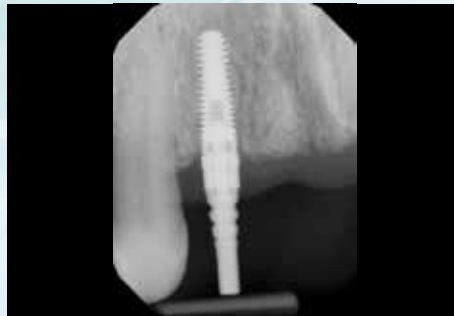

Figure 22: A radiograph was taken to verify complete seating of the impression coping.

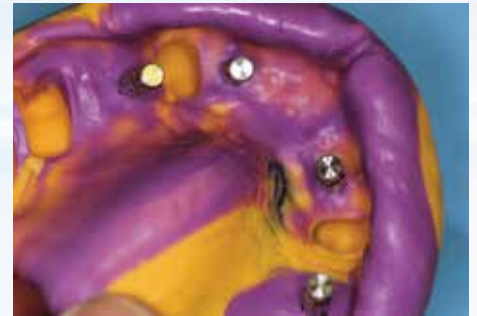

Figure 23: A final impression was taken with the remaining natural teeth in place and sent to the lab for fabrication of the final denture.

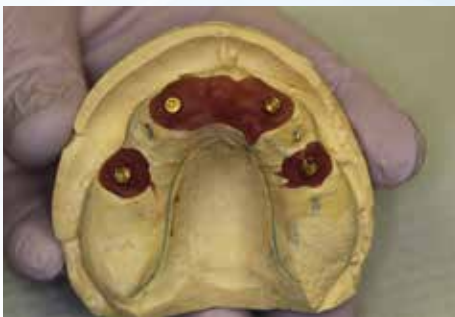
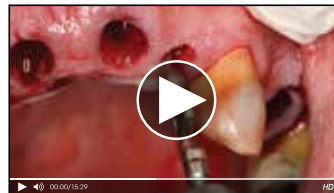
Figure 24: The laboratory removed the anchor teeth from the hard model and created a soft tissue model with the appropriate Locator abutments for fabrication of the final implant-retained prosthesis.

WATCH THE VIDEO



Dr. Kosinski narrates the case at www.inclusivemagazine.com

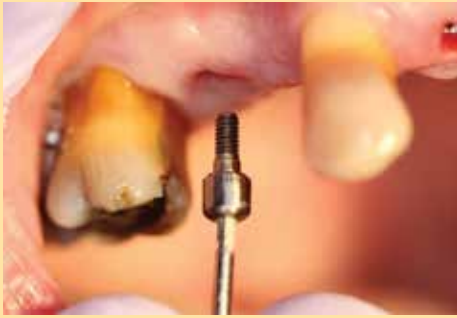

Figure 25: The healing abutments were removed from the implants.

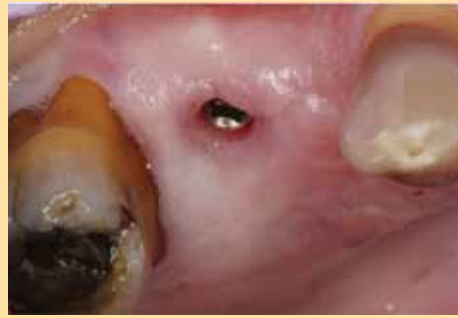

Figure 26: The peri-implant soft tissue exhibited healthy gingival cuffs upon removal of the healing abutments.

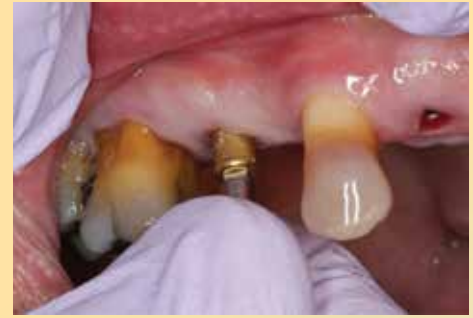

Figure 27: The Locator abutments were threaded into the implants.

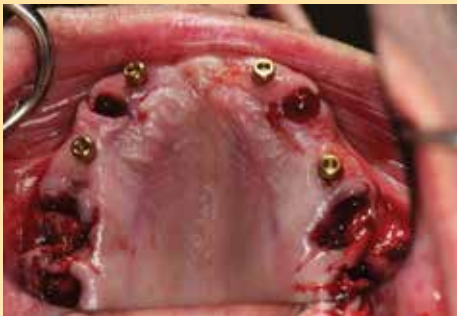

Figure 28: The remaining natural teeth were removed in preparation for delivery of the final implant-retained overdenture.

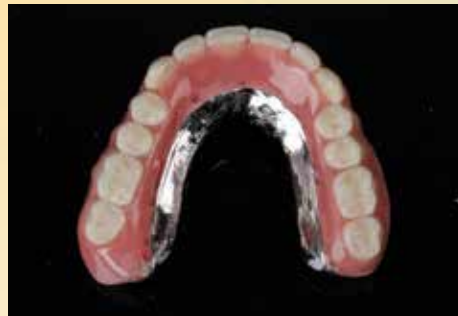

Figure 29: The final prosthesis was reinforced with metal for strength and featured a palateless design to enhance dental function, patient comfort and food-tasting capability.

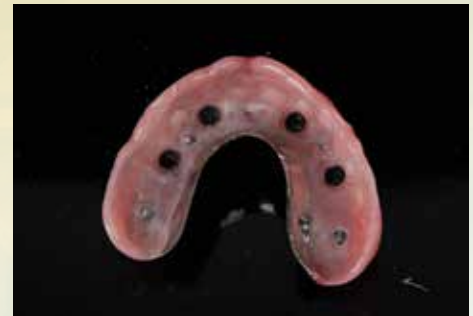

Figure 30: The final maxillary overdenture incorporated four Locator retention caps, which provide excellent prosthetic stability by affixing to the Locator abutments.

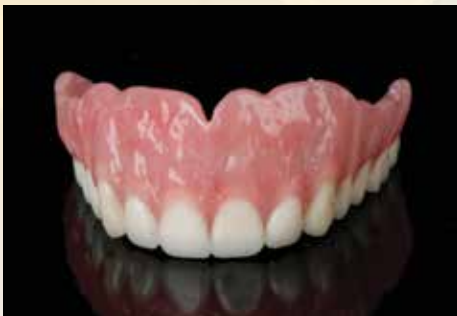

Figure 31: The lab produced the final overdenture with a high flange to accommodate the patient's thin upper lip, enhance his smile line and maximize facial support.

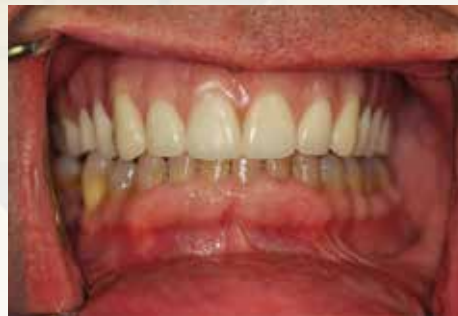

Figure 32: Retracted view of final maxillary overdenture in place, which offers long-term stability, function and support of the patient's tissue and facial structures.

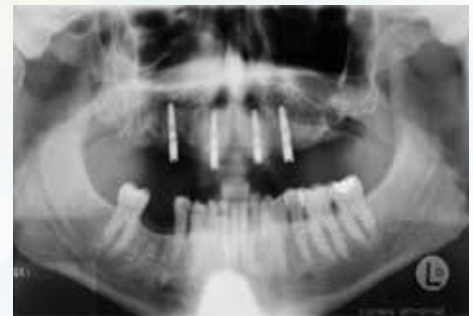

Figure 33: Panoramic radiograph of the parallel-placed implants following osseointegration.

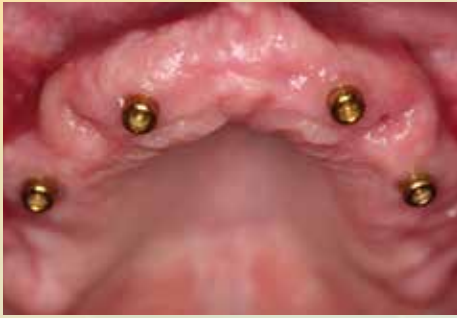

Figure 34: The maxillary ridge had healed nicely four weeks after extracting the remaining natural teeth.

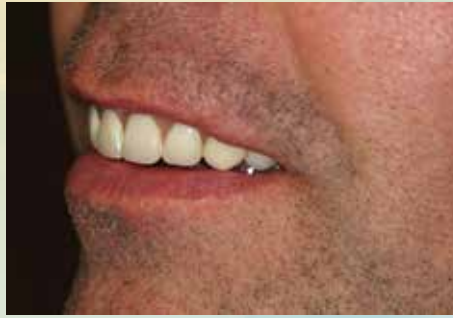

Figure 35: Left lateral view of the final prosthesis in place demonstrates the dramatically improved esthetics provided by the appliance, addressing the patient's predominant dental concerns.

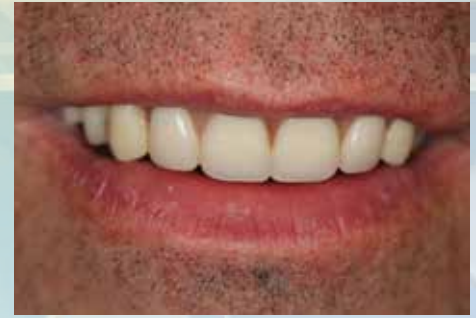

Figure 36: Frontal view exhibits the natural-looking appearance and improved smile line provided by the final implant-retained overdenture, greatly enhancing the patient's confidence.

CONCLUSION

Sequential treatment planning ensured that the patient was never without a stable maxillary prosthesis. The horseshoe-shaped maxillary transitional appliance relied on the natural anchor teeth for support. Following integration and removal of the remaining teeth, the four Locator attachments retained and stabilized the new maxillary implant-retained palateless overdenture. The improved esthetics, pain relief and long-term function offered by the final restoration has significantly improved the patient's quality of life.

Whether the need for treatment revolves around health, function or esthetics, implant-supported restorations have the capacity to impact patients in life-changing ways. The ideal restoration can be visualized during case planning and carried through each step of treatment until delivery of the final restoration.

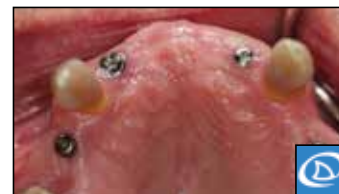For patients with edentulism or severe dental conditions, this allows clinicians to greatly improve esthetics and restore the mouth to a natural-looking state. Implant-retained dentures provide long-term prosthetic stability along with support of the oral and facial soft tissue, which can bolster patient confidence and alleviate insecurity.

With the convergence of technology, product innovations and flexible treatment protocols, implant therapy has proven to be an excellent treatment option for a wide array of dental conditions. **IM**

REFERENCES

1. Rossein KD. *Alternative treatment plans: implant-supported mandibular dentures.* *Inside Dentistry.* 2006;2(6):42-3.
2. Covani U, Cornellini R, Calvo JL, Tonelli P, Barone A. *Bone remodeling around implants placed in fresh extraction sockets.* *Int J Periodontics Restorative Dent.* 2010 Dec;30(6):601-7.
3. DiMatteo A. *Dentures and implants: bringing them together for a winning combination.* *Inside Dentistry.* 2009;5(1):97-104.

EARN CE CREDIT



Take a CE test on this case at
www.inclusivemagazine.com