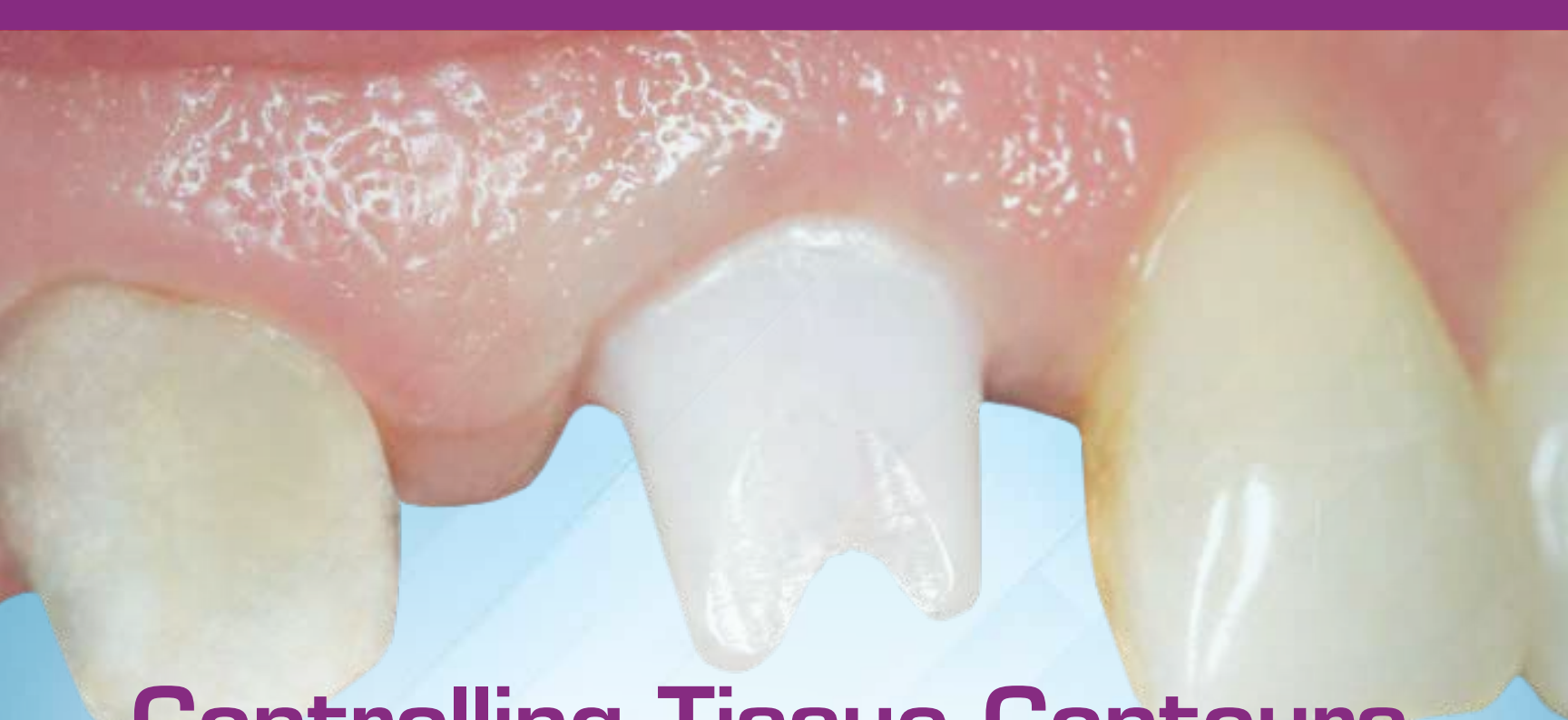

Controlling Tissue Contours

with a Prosthetically Driven Approach to Implant Dentistry



Go online for
in-depth content

by *Timothy F. Kosinski, DDS, MAGD*



With continual improvements in the design and production of implant systems and restorative components, the consistent results, predictability and long-term prognosis offered by implant therapy is making the treatment an increasingly popular technique for replacing missing teeth. The esthetics, durability and precise customization offered by modern prosthetic components enable clinicians to provide ideal final restorations their patients can depend on.

For the best results and maximum efficiency, implant therapy should be approached comprehensively, with the final result visualized from the outset. Technology has advanced to the point where smile design, emergence profile and margins can be established prior to any surgical intervention, giving clinicians a clear picture of the optimal prosthetic outcome that can be carried through each phase of treatment.

The Inclusive[®] Tooth Replacement System (Glidewell Laboratories; Newport Beach, Calif.) simplifies this approach by providing everything needed for an implant case in a single

package, building toward the final restoration with patient-specific components that begin shaping the patient's soft-tissue contours immediately following surgery. Experienced dental technicians use the latest in CAD/CAM technology to design custom abutments that sculpt the gingival contours during the healing phase, setting up a smooth, predictable transition to the final custom abutment and crown.

Until recently, surgical placement of the implant was the primary concern. Improvements in dental implant design have led to better initial stability and less crestal bone loss over time. While positioning and angulating the implant to accommodate the patient's underlying anatomy and bone morphology is crucial, achieving the most esthetic final result possible is also now of paramount importance if seeking to meet or exceed patient expectations.

The Inclusive Tooth Replacement System takes significant strides in facilitating the creation of superior, more predictable esthetics. With the optimal emergence profile driving the design process, clinicians now have the necessary tools

While positioning and angulating the implant to accommodate the patient's underlying anatomy and bone morphology is crucial, achieving the most esthetic final result possible is also now of paramount importance if seeking to meet or exceed patient expectations.

to manage soft-tissue contours with custom components that approximate the root design and structural anatomy of a natural tooth.

The case that follows illustrates how an all-inclusive, prosthodontically driven treatment protocol assists the clinician in achieving an excellent clinical outcome while streamlining the surgical and restorative phases of treatment. Because the case involves the replacement of a central incisor in the anterior, where creating an ideal emergence profile is especially important, the esthetic benefits of this approach are particularly evident.

Physiologically, anterior implants should be placed, relative to the adjacent natural teeth, approximately 3.0 mm palatal to the facial plane, 3.0 mm apical to the cemento-enamel junction (CEJ) and 2.0–3.0 mm from the periodontal ligaments. When a central incisor needs to be replaced with an implant restoration following extraction of a nonrestorable tooth root, an understanding of these considerations is essential. A central incisor tooth is shaped to be wider in the mesial-distal dimension than the facial-palatal dimension. The implant should not be placed directly into the socket site created by the extraction, because the facial bone is often very thin. Placing the implant slightly off center, toward

the palate, will create a better prosthetic emergence and help establish an ideal final result. With correct placement of the implant at the crest of bone, the interdental papilla are allowed to fill in properly, thus encouraging more natural crown margins.

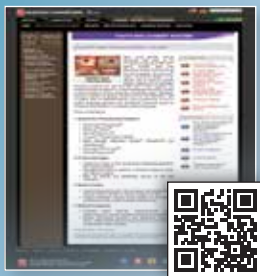Once the nonrestorable tooth is removed and the implant is placed, a custom healing abutment can be threaded into the implant. This trains the soft tissue during healing to form contours similar to the gingival anatomy that surrounded the natural tooth root prior to removal. The gingival contours of the tooth being replaced are thus retained or even improved upon. The Inclusive Tooth Replacement System also includes a custom-milled transitional abutment and crown should the practitioner, in the presence of adequate primary stability, decide to load the implant upon placement. In either situation, the soft tissue and interdental papilla are shaped to accommodate the final restoration.

Following integration of the implant and healing of the soft tissue, a custom impression coping with matching gingival contours is used to precisely capture the resulting sulcus and surrounding tissue form when taking the final impression. The laboratory then preserves the tissue contours in the final zirconia or titanium abutment and provides the final crown. Throughout the process, the gingiva is shaped for a natural emergence profile that cannot be achieved with the cylindrical form of a stock healing abutment. There is little or no blanching of tissue during the impression process or even during the placement of the final custom abutment and crown.

CASE REPORT

A 55-year-old female with no medical concerns presented with a fractured maxillary left central incisor. Endodontic referral indicated that the tooth was untreatable. Options discussed with the patient included a conventional 3-unit bridge or a dental implant restoration to replace the central incisor. After careful intraoral and radiographic examination,

Go Online



Custom healing components are now available individually, expanding the benefits of patient-specific soft-tissue contouring to more patients. For information on how to use custom healing components with an implant system or restorative dental lab of choice, visit the Inclusive® Tissue Contouring System page under Implants, then Tooth Replacement Systems at www.glidevelldental.com.

it was determined that an implant could be predictably placed in the bone without complication. The primary goal was for the ultimate emergence profile of the final restoration to match that of the natural tooth being replaced and that of the adjacent central incisor.

The approximate position of the dental implant was determined in the hard model, establishing the ideal location 3.0 mm apical to the adjacent CEJ. A flapless surgical protocol was selected to retain as much gingival tissue as possible and minimize shrinkage. The laboratory produced a prosthetic stent to assist with the initial orientation of the pilot drill. A radiograph was taken to ensure proper mesial-distal positioning and equal spacing between the implant site and the adjacent natural teeth. Once proper angulation was verified, typical implant techniques were used.

Treatment began with the atraumatic extraction of the root of the maxillary left central incisor. Maintaining the facial plate of bone was critical to facilitating optimal tissue healing and allowed for flapless placement of the dental implant. Proper depth for the implant was determined, using the apices of the adjacent teeth as a guide to reduce the risk of damaging any critical anatomy. Digital radiographs were used before, during and after the surgical procedure to ensure ideal implant angulation and depth. A pilot drill established the desired depth. Per typical guidelines for implant placement, the apex of the implant was safely and effectively positioned in line with the roots of the adjacent teeth. The other drills used during the procedure expanded the osteotomy to the proper width.

Following implant placement, the choice was made to not immediately load the implant with a transitional crown because sufficient primary stability was not achieved. The custom healing abutment was placed, and because the tooth being replaced was in the esthetic zone, a removable partial denture was used as a transitional appliance. The custom contours of the healing abutment mimicked those of the natural tooth being replaced, and effectively managed the patient's soft tissue. Upon completion of the healing phase, ideal gingival contours were evident, which made delivery of the final restoration a smooth endeavor that was comfortable for the patient and required no chairside adjustments.

Clinicians now have the necessary tools to manage soft-tissue contours with custom components that approximate the root design and structural anatomy of a natural tooth.

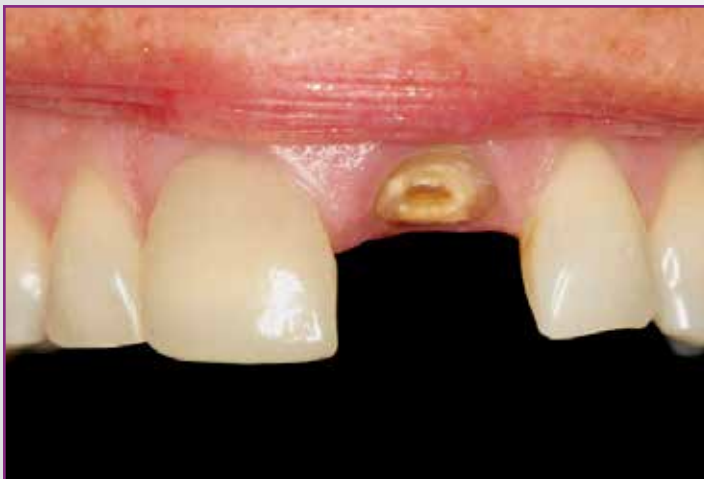

Figure 1: The patient presented with a fractured root on tooth #9 with interdental papilla intact.

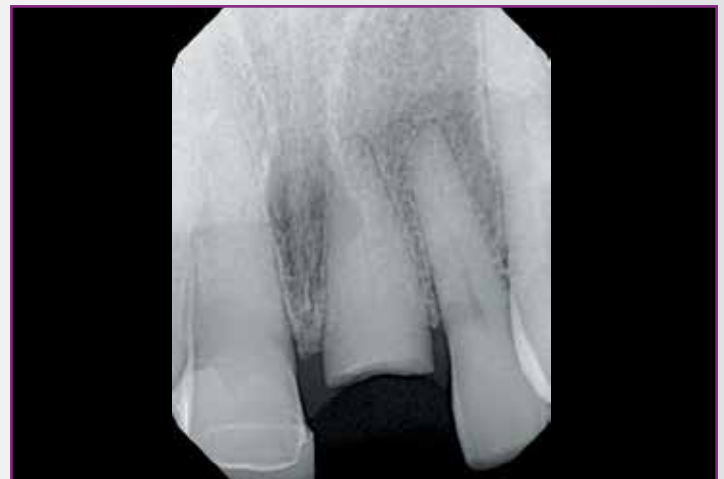

Figure 2: Preoperative digital periapical radiograph of the nonrestorable maxillary left central incisor.

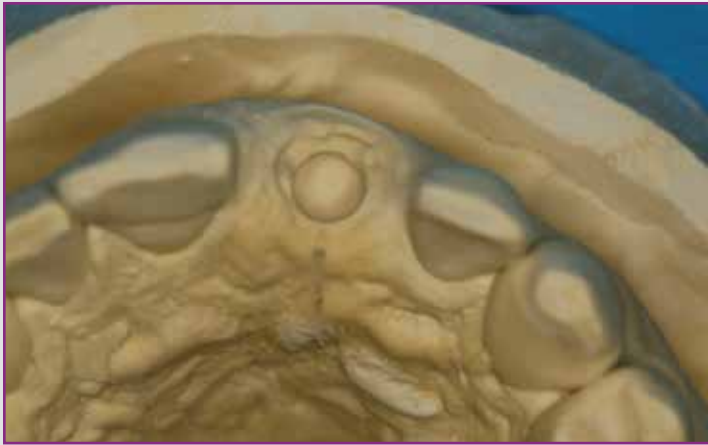

Figure 3: A hard model was prepared to approximate the eventual implant position and tissue contours.

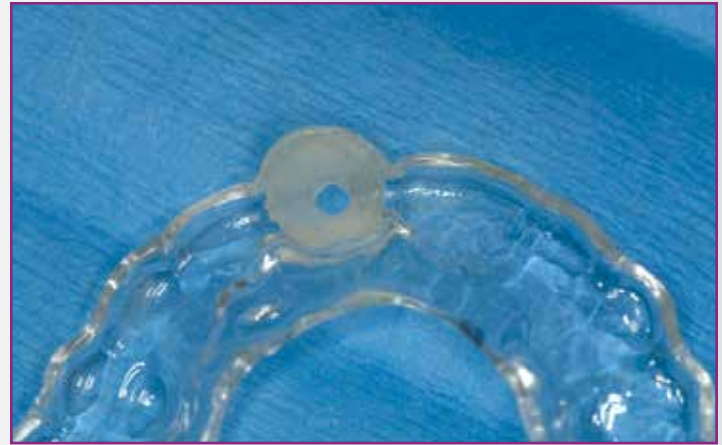

Figure 4: A prosthetic stent was created to help ensure accurate positioning of the implant.

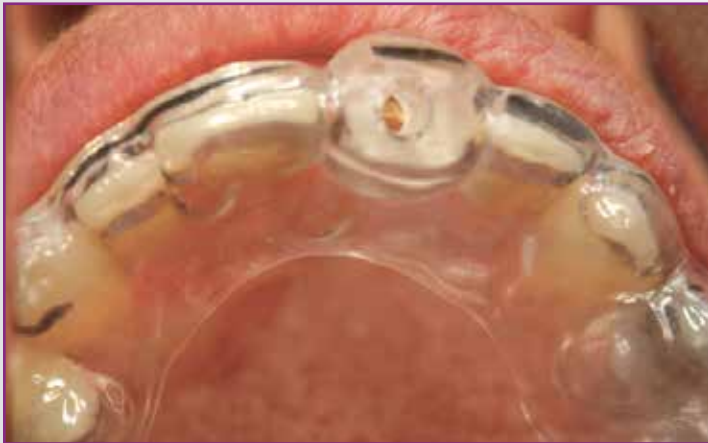

Figure 5: The prosthetic stent, which would allow for ideal positioning of the pilot drill when creating the osteotomy, was tried in.

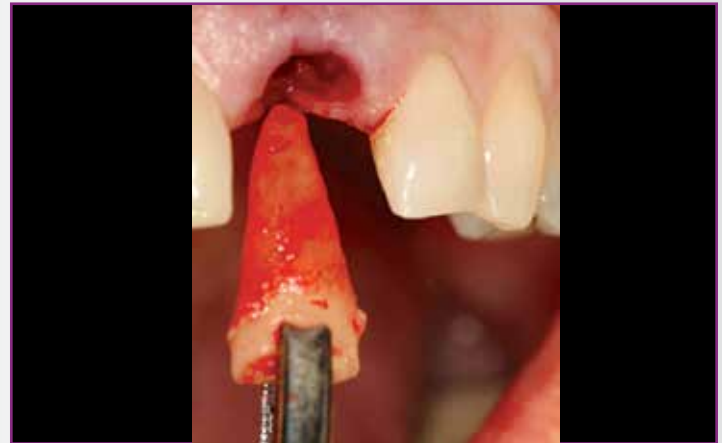


Figure 6: Atraumatic extraction of the root was achieved using Physics® Forceps (Golden Dental Solutions Inc.; Detroit, Mich.), maintaining the facial plate of bone.

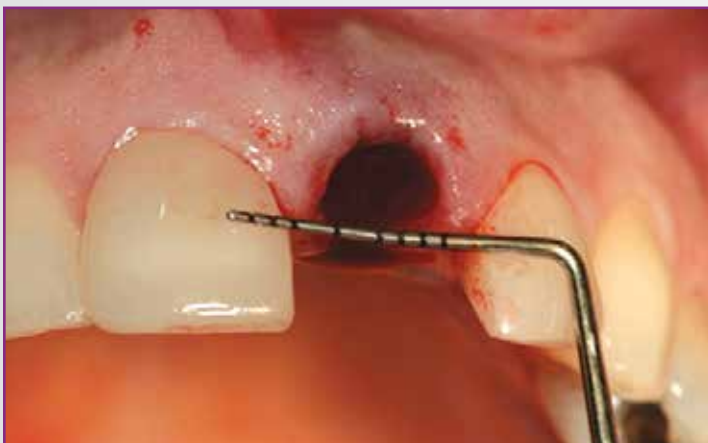

Figure 7: Measuring the facial plane between the natural adjacent teeth demonstrated the proper position for the pilot drill.

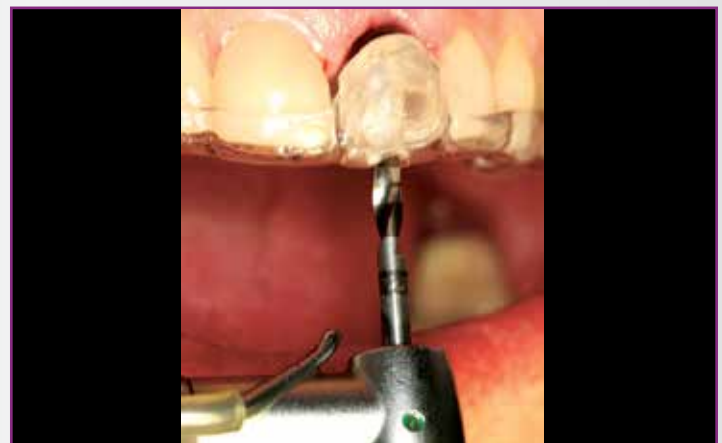
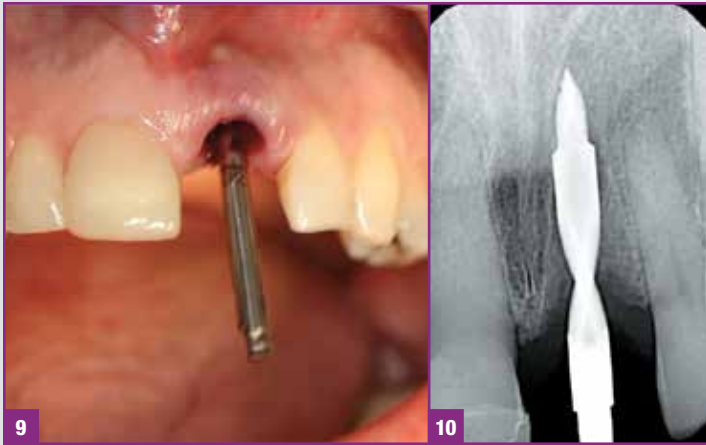
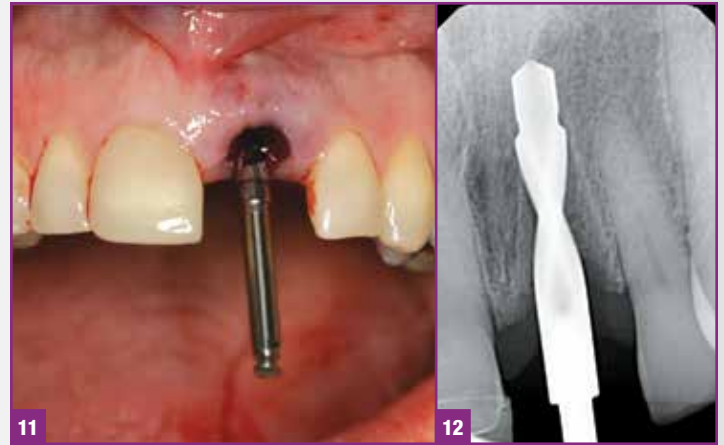


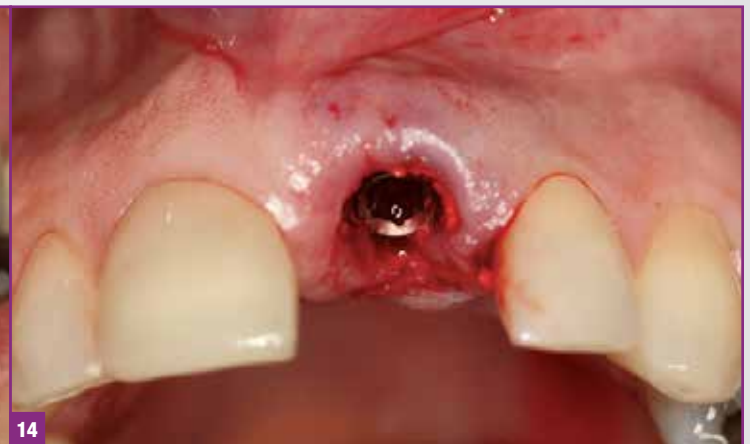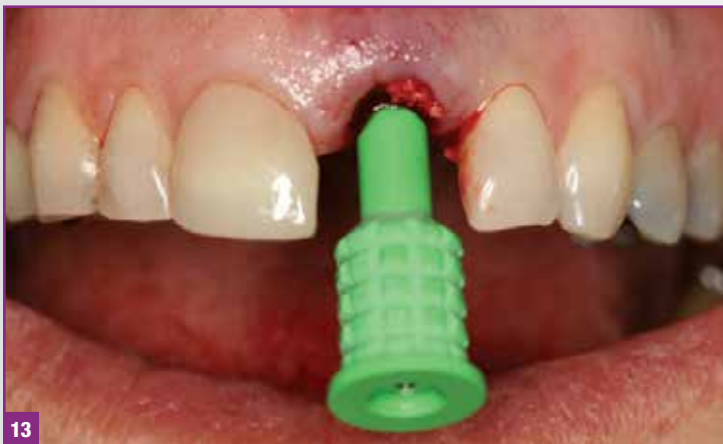Figure 8: A pilot drill was used to create the initial osteotomy.



Figures 9, 10: The pilot drill was left engaged with the bone, and a radiograph was taken to confirm that the angulation and depth of the osteotomy adhered to the desired parameters of the final restoration.



Figures 11, 12: The osteotomy was widened with subsequently larger surgical drills. Radiographs were taken frequently to confirm proper positioning of the implant site.



Figures 13, 14: An Inclusive® Tapered Implant (Glidewell Direct; Irvine, Calif.) was initially hand tightened into place using the accompanying tactile carrier.

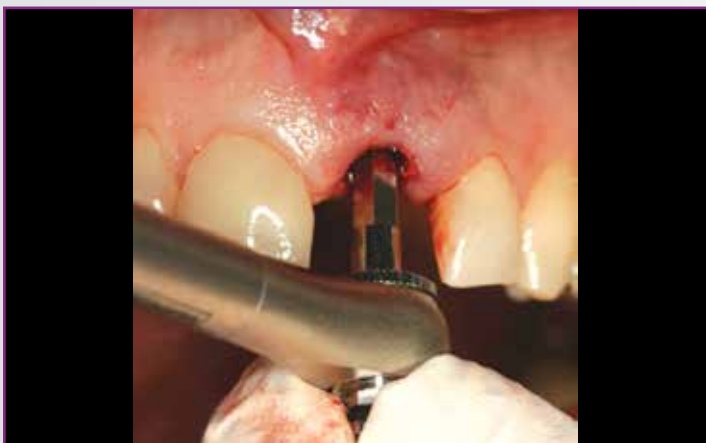

Figure 15: The implant was torqued until fully seated.

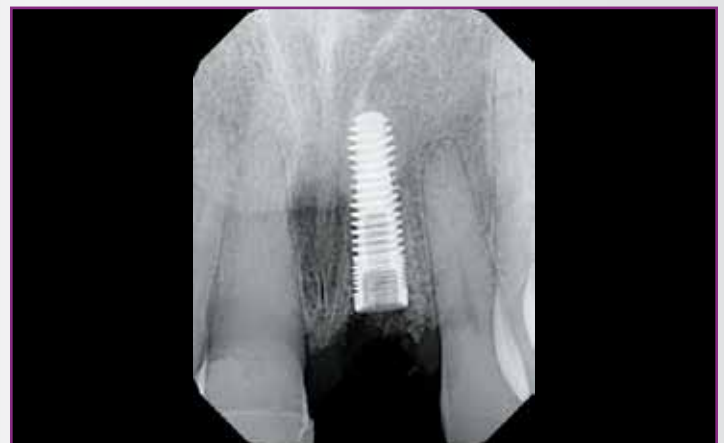

Figure 16: A radiograph of the fully seated implant confirmed accurate placement.

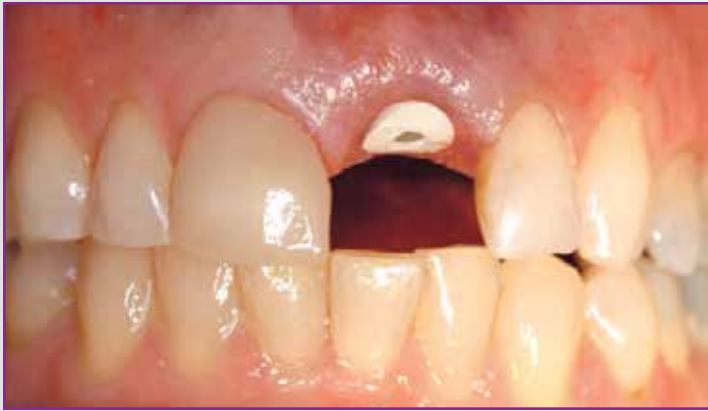

Figure 17: Because the implant did not demonstrate sufficient primary stability upon final seating, a custom healing abutment with patient-specific contours was placed, mirroring the position and form of the extracted tooth root. NOTE: Inclusive custom healing components are milled from biocompatible polyether ether ketone (PEEK) material, allowing for adjustments and relinings to establish proper fit in instances where the implant does not end up at the exact depth or orientation planned on the model.

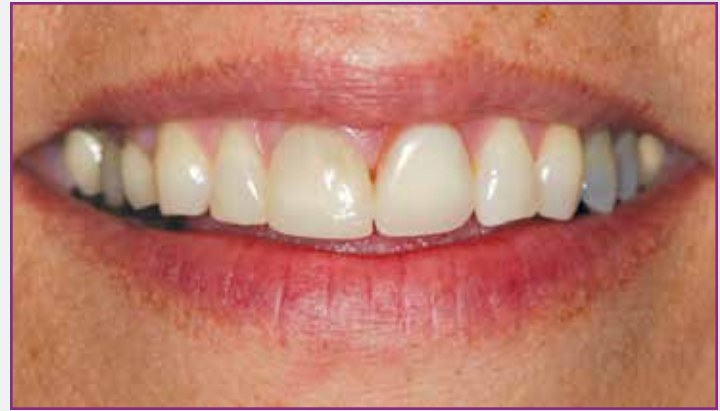

Figure 18: A removable flipper appliance was used as a transitional prosthesis during the healing phase.

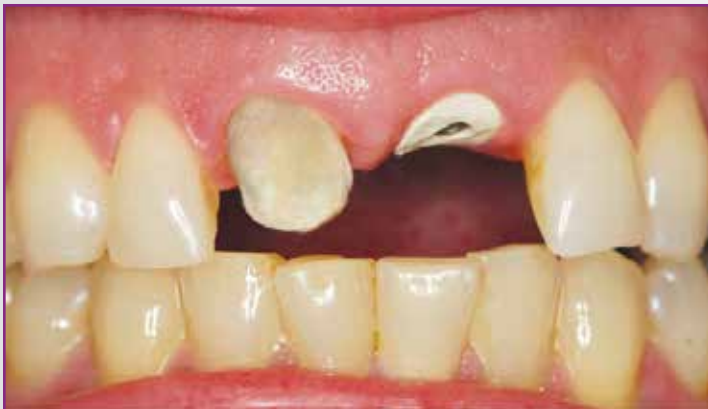

Figure 19: After four months of integration, the soft tissue had healed nicely around the custom healing abutment, exhibiting optimal margins and gingival contours. For esthetics, the maxillary right central incisor crown would be replaced following preparation.

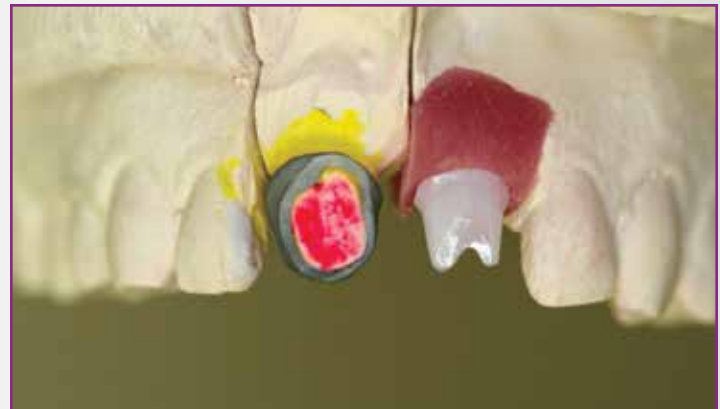

Figure 20: After an impression was taken using the custom impression coping, the lab fabricated the final zirconia abutment and confirmed proper fit, margins and emergence profile on the working model.

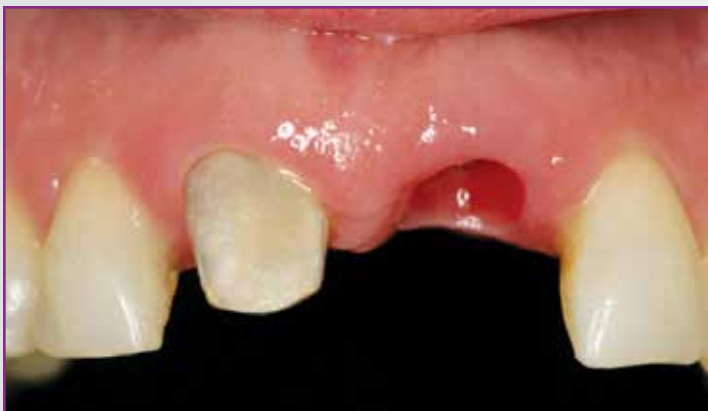

Figure 21: Removal of the custom healing abutment revealed beautifully contoured tissue.

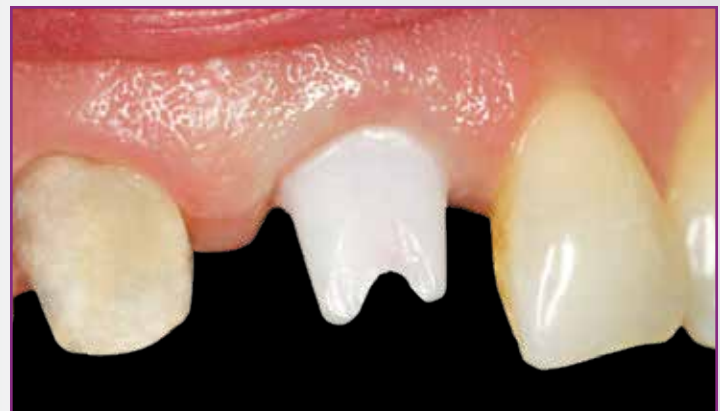
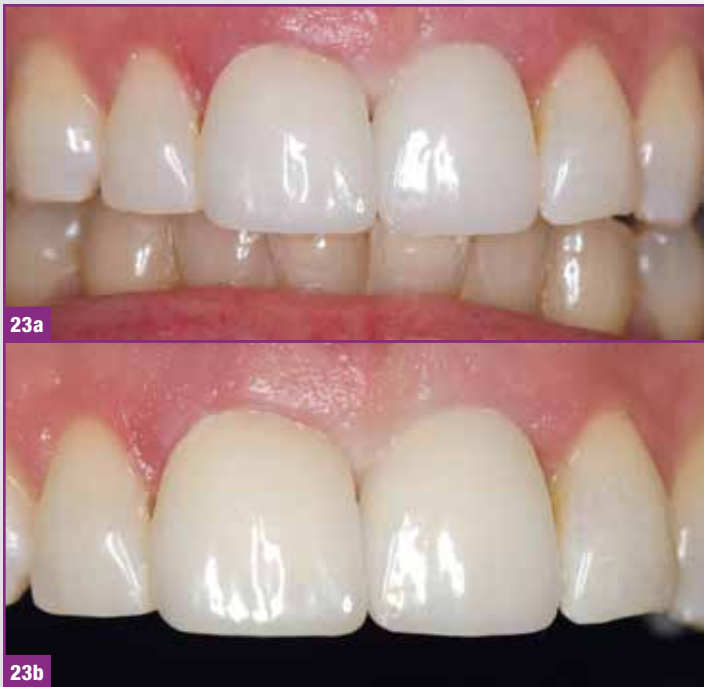
Figure 22: The final zirconia abutment was delivered with ease and adhered nicely to the controlled gingival architecture established during the healing phase.



Figures 23a, 23b: Final central incisor crowns in position. The optimal esthetics exhibited by the soft tissue and implant crown were set up by the patient-specific contours of the custom healing abutment.

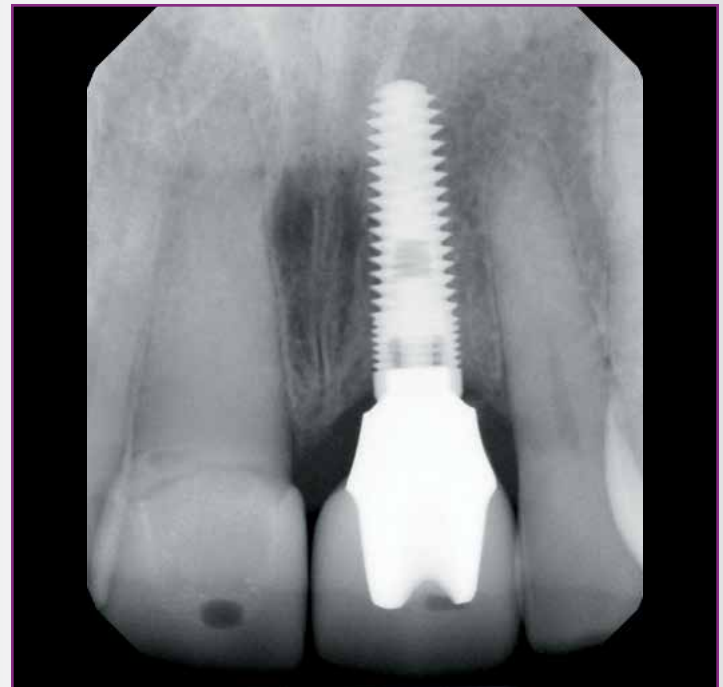

Figure 24: Final periapical radiograph of the implant abutment and crown in place exhibits the natural emergence profile of the final restoration.

CONCLUSION

As demonstrated by the natural margins, soft-tissue contours and emergence profile achieved in this case, a prosthetically driven approach to implant dentistry provides excellent clinical outcomes. Visualizing the final restoration from diagnosis and treatment planning through delivery of the final abutment and crown helps to ensure a predictable result. The Inclusive Tooth Replacement System simplifies this approach by harnessing patient-specific tissue contouring and an all-inclusive clinical protocol to guide cases toward a functional and esthetic conclusion, with each step of the restorative process setting up the next for success.

Cutting-edge CAD/CAM design and manufacturing techniques were used in this case to produce custom-milled components that managed the patient's soft tissue during healing to facilitate a smooth and comfortable delivery of the final prosthesis. This approach facilitates predictable clinical results for all implant restorations and is especially important for cases in the anterior, where esthetics, soft-tissue contours, interdental papilla and emergence profile are essential.

Prosthetic techniques have advanced to the point where fabrication of a final implant-retained crown can be as easy as

that of a conventional crown. Smile design and emergence profile considerations are addressed by properly planning cases in tandem with specially trained dental laboratory technicians to incorporate a restorative-driven treatment protocol. By providing all of the implant and prosthetic components along with the laboratory customization needed to control tissue contours in one package, the Inclusive Tooth Replacement System saves the practitioner significant time and effort that would otherwise be spent coordinating and arranging for individual parts and laboratory services. This proved to be an outstanding treatment modality in a difficult esthetic circumstance. **IM**

GENERAL REFERENCES

1. Locante WM. Single-tooth replacements in the esthetic zone with an immediate function implant: a preliminary report. *J Oral Implantol.* 2004;30(6):369-75.
2. Degidi M, Piattelli A. Comparative analysis study of 702 dental implants subjected to immediate functional loading and immediate nonfunctional loading to traditional healing periods with a follow-up of up to 24 months. *Int J Oral Maxillofac Implants.* 2005 Jan-Feb;20(1):99-107.
3. Villa R, Rangert B. Early loading of interforaminal implants immediately installed after extraction of teeth presenting endodontic and periodontal lesions. *Clin Implant Dent Relat Res.* 2005;7 Suppl:S28-35.
4. Babbush CA. Provisional implants: surgical and prosthetic aspects. *Implant Dent.* 2001;10(2):113-20.